

# Ruptured pseudoaneurysm of coronary artery bypass graft

Kathleen Thayse \*, Stéphane Baldassarre , and Stéphane Carlier 

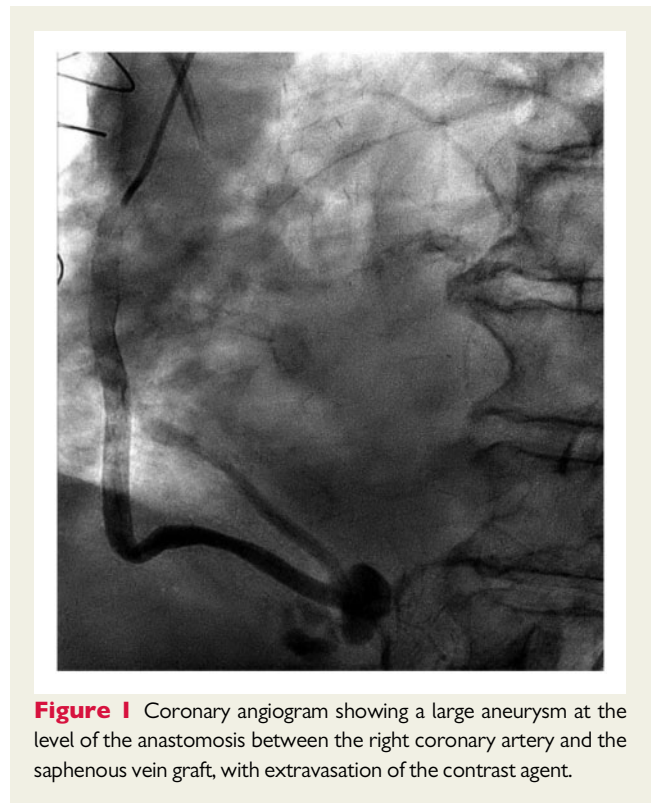
Department of Cardiology, University Hospital Center Ambroise Paré, Mons, 7000 Mons, Belgium

Received 31 August 2020; first decision 15 September 2020; accepted 24 November 2020

A 76-year-old patient who was hospitalized with septic arthritis and developed acute chest pain after going to the toilet, and this pain persisted at rest. An electrocardiogram (ECG) showed a third-degree atrioventricular block, new T-waves inversion in inferior leads ([Supplementary material online, Figure S1](#)) and known lateral ST depressions, which were higher than on an ECG recorded 2 years previously ([Supplementary material online, Figure S2](#)). His past medical history is notable for a triple coronary artery bypass graft (CABG) post-myocardial infarction, with left internal mammary artery to left anterior descending artery arterial graft and saphenous vein grafts (SVGs) aorta (Ao)-circumflex artery and Ao-right coronary artery (RCA). An urgent coronary angiogram was performed within 1 h and showed three patent grafts, but an aneurysm was detected at the level of the SVG-RCA anastomosis with a diameter of 22 mm, as measured by quantitative coronary angiography. There was some extravasation of the contrast agent ([Figure 1, Video 1](#)).

Transthoracic echocardiography was urgently performed and showed a significant pericardial effusion compressing the right ventricle ([Figure 2, Video 2](#)). It is possible that an associated haematoma (dry tamponade) compressed the branches of the RCA irrigating the atrioventricular node, which could explain the atrioventricular block. An external pacemaker was implanted but no invasive mechanical support was given. Due to the possibility of a fast transfer to a cardiac surgery centre, the cardiologist in charge did not attempt to perform a pericardiocentesis, not to delay the surgery. The patient was admitted to the intensive care unit before his transfer to a cardiac surgery centre. Unfortunately, he passed away from worsening cardiogenic shock before the cardiac surgeon could intervene.

Saphenous vein graft aneurysm post-CABG is rare and defined as a >1.5 times focal dilatation of the proximal vessel diameter reference. It occurs predominantly in men, at the level of the RCA graft and is generally asymptomatic. The choice of percutaneous closure



**Figure 1** Coronary angiogram showing a large aneurysm at the level of the anastomosis between the right coronary artery and the saphenous vein graft, with extravasation of the contrast agent.

(Amplatzer occluder or coil embolization) vs. surgical management of the aneurysm depends on anatomical features, the presence of complications and patient comorbidities. Surgical resection remains the first-line therapy in the case of mechanical complications (such as fistula, rupture or compression of adjacent cardiac or vascular

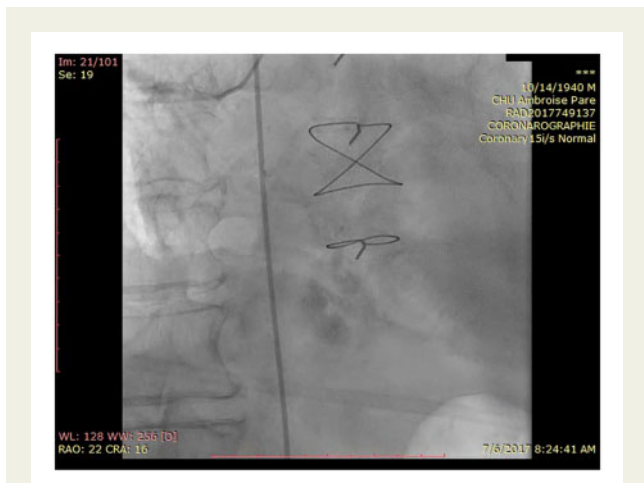
\* Corresponding author. Tel: +32 6 537 3381, Email: [stephane.carlier@umons.ac.be](mailto:stephane.carlier@umons.ac.be)

Handling Editor: Aref Bin Abdulhak

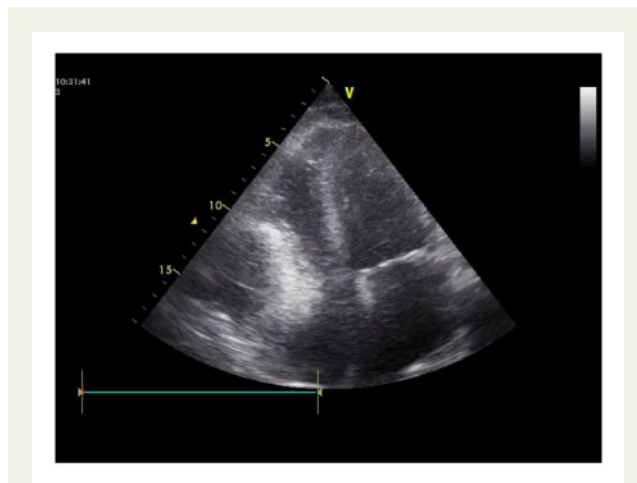Peer-reviewers: Luigi Biasco, Mohamed Farag and Arvind Singh

© The Author(s) 2020. Published by Oxford University Press on behalf of the European Society of Cardiology.

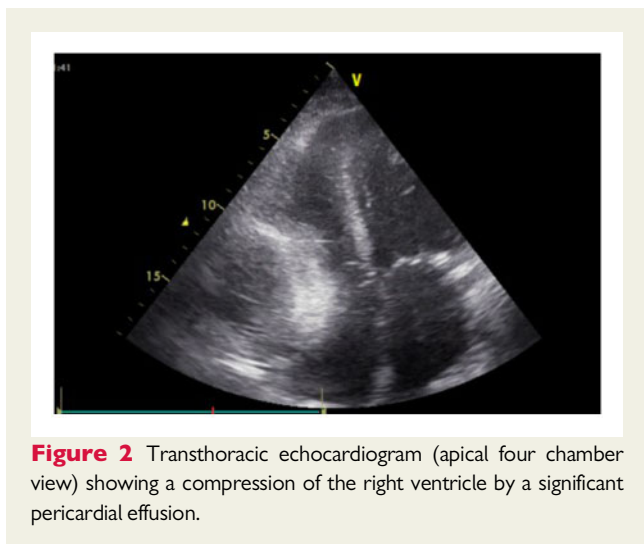
This is an Open Access article distributed under the terms of the Creative Commons Attribution Non-Commercial License (<http://creativecommons.org/licenses/by-nc/4.0/>), which permits non-commercial re-use, distribution, and reproduction in any medium, provided the original work is properly cited. For commercial re-use, please contact [journals.permissions@oup.com](mailto:journals.permissions@oup.com)



**Video 1** Coronary angiogram showing a large aneurysm at the level of the anastomosis between the right coronary artery and the saphenous vein graft, with extravasation of the contrast agent.



**Video 2** Transthoracic echocardiogram (apical four chamber view) showing a compression of the right ventricle by a significant pericardial effusion.



**Figure 2** Transthoracic echocardiogram (apical four chamber view) showing a compression of the right ventricle by a significant pericardial effusion.

structures). If the graft remains patent with a suitable anatomy for stenting, the aneurysm can be treated with a covered stent. Available

knowledge is based only on a few published cases and standardized treatment strategies are therefore lacking.<sup>1,2</sup>

Certainly balloon, coil or device occlusion could have been an option in our case, at the cost of the loss of RCA perfusion.

## Supplementary material

Supplementary material is available at *European Heart Journal - Case Reports* online.

**Consent:** The author/s confirm that written consent for submission and publication of this case report including image(s) and associated text has been obtained from the relatives of the patient in line with COPE guidance.

**Conflict of interest:** none declared.

## References

- Ramirez FD, Hibbert B, Simard T, Pourdjabbar A, Wilson KR, Hibbert R et al. Natural history and management of aortocoronary saphenous vein graft aneurysms: a systematic review of published cases. *Circulation* 2012;**126**:2248–2256.
- Kawsara A, Núñez Gil IJ, Alqahtani F, Moreland J, Rihal CS, Alkhouli M. Management of coronary artery aneurysms. *JACC Cardiovasc Interv* 2018;**11**: 1211–1223.